



PATIENT
Moe Skorupa

SPECIES
Feline

BREED
DLH

SEX
Female Spayed

AGE
5 years

WEIGHT
8.6lbs

INTERPRETED BY
Maggie Machen
Lamy, DVM
DACVIM (Cardiology)

IMAGING PERFORMED BY
Pamela Harrigan,
RDCS

HOSPITAL NAME
Mass Veterinary Services

REFERRING VET
Dr. Masloski

INVOICE
26094

DATE
8/30/22

PRESENTING CLINICAL SIGNS

History: Moe was noted to have a heart murmur in March 2019. An echocardiogram done in February 2021 revealed a 0.16cm left to right VSD (report not available). She is doing well - good appetite and activity level. On exam: NSR, grade I/VI parasternal murmur, PSS, lung fields clear, compressible thorax. BP: 100-110mmHg *Sedated with propofol for study.

ECHOCARDIOGRAM FINDINGS

2D, m-mode, color flow and Doppler imaging is available.

Left ventricle: The LV diameter is normal with adequate myocardial function. The LV wall thicknesses are normal. The papillary muscles are normal. The endocardium appears mildly hyperechoic.

Left atrium: The left atrium is normal in dimension. No obvious spontaneous contrast or thrombi seen.

Mitral valve: The mitral valve is normal in structure and mobility. No obvious systolic anterior motion is seen. No MR.

Aortic valve/Aorta: The aortic valve is normal in morphology and mobility. Normal aortic outflow velocity; laminar flow. No aortic insufficiency.

Right ventricle: Normal right ventricular diameter and morphology indicating no overt evidence of pulmonary arterial hypertension.

Right atrium: The right atrium is normal in dimension.

Tricuspid valve: The tricuspid valve appears normal with trivial tricuspid regurgitation.

Pulmonic valve/Pulmonary artery: The pulmonic valve is normal in morphology and mobility. No pulmonic insufficiency. Normal RVOT velocity; laminar flow.

Pericardium/other: No pericardial or pleural effusion noted. No obvious cardiac masses.

2-Dimensional Measurements

Ao diam (cm)	1.0
LA diam (cm)	1.0
LA:Ao (Swe)	1.0
IVS thickness (cm)	0.37
LVID diastole (cm)	1.38
PW thickness (cm)	0.42
LVID systole (cm)	0.87
FS (%)	37

Doppler Measurements

PV Vmax (m/s)	0.56
AoV Vmax (m/s)	0.83
MR Vmax (m/s)	NA
TR Vmax (m/s)	NA
TR PG (mmHg)	NA

INTERPRETATION OF THE FINDINGS

Overtly normal cardiac structure and function. The LV wall thickness is normal and there is no evidence of elevated left atrial pressure. No VSD is identified on color flow or 2D imaging. No cause for the murmur is identified in this study (likely due to sedation), making it likely physiologic in origin (i.e., secondary to tachycardia, volume changes, etc.).

Prognosis is open.

RECOMMENDATIONS

- Given these findings, no medications are indicated.
- No cardiac contraindication for general anesthesia.
- Monitor for any clinical evidence of cardiac compromise, including respiratory changes and/or signs of a blood clot event (paralysis, neurologic changes, etc.).



PATIENT

Moe Skorupa

PLAN

- Recommend recheck echocardiogram in 1 year to reassess murmur origin and screen for development of disease the pre-existing murmur may mask.

SPECIES

Feline

BREED

DLH

SEX

Female Spayed

AGE

5 years

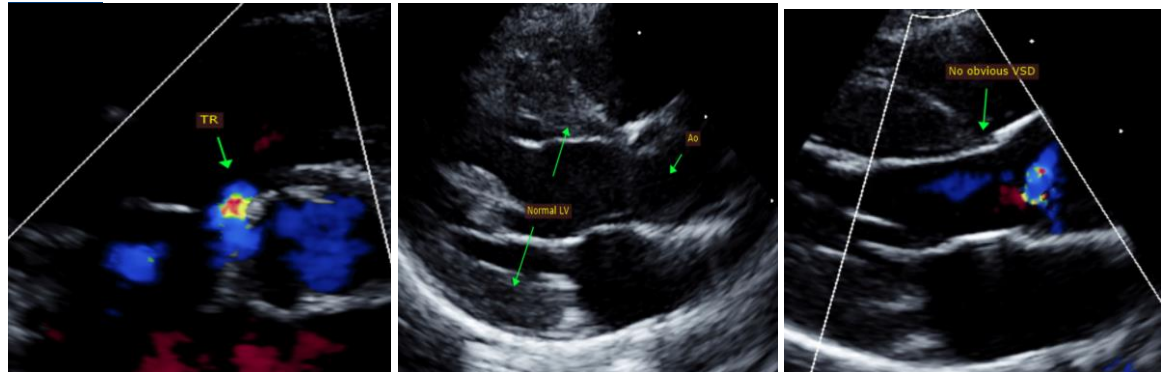
WEIGHT

8.6lbs

INTERPRETED BY

Maggie Machen
Lamy, DVM
DACVIM (Cardiology)

IMAGES



The information and recommendations provided are based on the images presented by the referring veterinarian. No evaluation can be communicated regarding pathology that was not visible in the image/video clips provided.

Thank you for this referral. This report was generated using transcription software, and minor dictation errors may be present. If the clinical or image interpretation does not parallel your findings or if I can be of any further assistance, please contact me.

Maggie Machen Lamy, DVM

Diplomate of the American College of Veterinary Internal Medicine (Cardiology)

info@sonopath.com

Echocardiogram performed by:

Pamela Harrigan, RDCS

Pet Animal Ultrasound Service (4paus.com)

IMAGING PERFORMED BY

Pamela Harrigan,
RDCS

HOSPITAL NAME

Mass Veterinary
Services

REFERRING VET

Dr. Masloski

INVOICE

26094

DATE

8/30/22